

Ulnar Dimelia

"Mirror Hand Deformity"

Ulnar Dimelia, commonly called mirror hand, is an extremely rare congenital anomaly of the upper limb. It is characterized by the duplication of the ulna, absent radius, and seven to eight well-formed digits. There is no thumb. All the elements of the radial axis; i.e. the 1st metacarp, the trapezium, trapezoid, and the scaphoid, are absent. Here after, a case of a 5-year-old male child with no thumb, eight triphalangeal digits symmetrically positioned around the central axis. On x-ray, there are two ulnae.

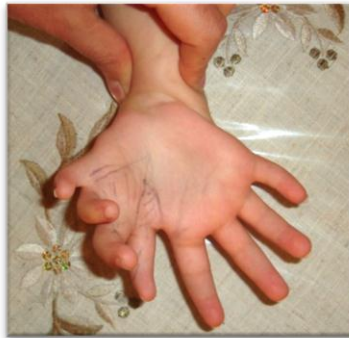

Figure (1)

Right hand- Palmar view

To the left, the four essential digits. To the right, the four extra digits.
The eight triphalangeal digits are symmetrically positioned regarding the central axis.

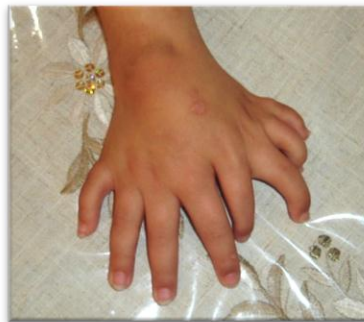

Figure (2)

Right hand- Dorsal view

To the right, the four original digits. To the left, the four duplicated digits.
There is no thumb. One could easily notice the increased width of the wrist.

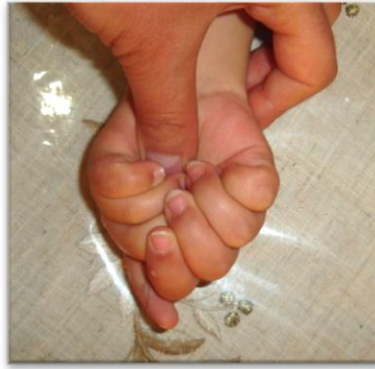

Figure (3)

Right hand- Fist formation

While flexing the digits, their tops seek the central axis but the extra (radial) index fails flexing. Failure of active flexion excluded the extra index from the list of choice of the future thumb. (My thumb is trying to fix the patient's wrist in order to support his weak wrist extensors.)

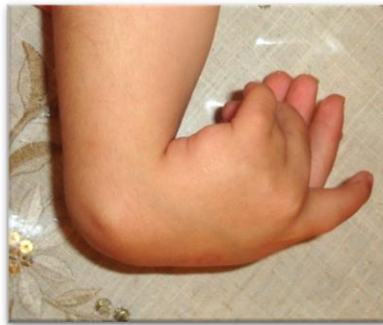

Figure (4)

Right hand- The extra hand (mirror hand) in the front

In spite of the complete active flexion of the wrist (effort tenodesis), the four extra (radial) metacarpophalangeal joints are still in the flexion position. Whereas, the four ulnar digits (in the back of the photo) take a more extension position. That is explained by the absence, or the hypoplasia, of the extra common extensor of the mirror (extra) digits.

The common digits extensor of the ulnar fingers is in full activity.

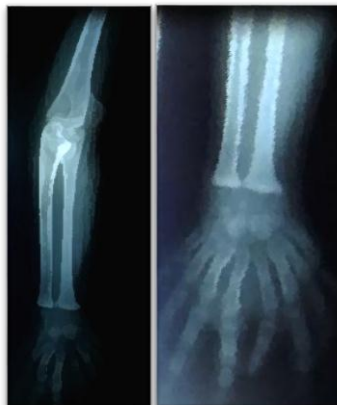

Figure (5)

X-ray of the right forearm and the right hand

The ulna is duplicated, they face each other. The radius is absent. Similarly, we can not find the thumb nor its supporting bony structures; i.e. the 1st metacarpe, the trapezium, the trapezoid, and the scaphoid.

One could count eight metacarpes with eight triphalangeal digits.

Discussion

Ulnar dimelia is an extremely rare congenital anomaly of the upper limb. There are no more than one hundred cases in the medical literature. It is characterized by the duplication of ulna. The radius is absent. In fact, all the radial structures; i.e. the 1st metacarpe, the trapezium, the trapezoid, and the scaphoid, are completely absent. In contrast, one finds seven to eight triphalangeal fingers.

Al- Qattan and Al Thunayan et el classified the ulnar dimelia deformity in five categories: 1) Two ulnae and no radius. 2) Two ulnae and one radius. 3) One ulna and one radius. 4) Syndromal mirror hand. 5) Multiple hand.

A 5-year-old male child was brought to my clinic. He had a right hand with eight well-formed fingers. The thumb was completely absent. The right wrist was larger than the left one. The flexion of the wrist and the fingers was total with the exception of the extra (radial) index whose flexion was incomplete. Similarly, we could recognize some weakness in the extensor of the four radial (extra) fingers and of the wrist extensors. The right elbow was unable to flex nor rotate. On X-ray, there were two ulnae and no radius. In fact, the total bony structures of the radial axis; i.e. the radius, the scaphoid, the trapezium, trapezoid, the 1st metacarpe, the thumb, were absent. There were eight metacarpes, and eight fingers with three phalanges for each.

The management of ulnar dimelia has two targets;

- 1- Ablation of the extra (radial) fingers except one needed for the next step;
- 2- Pollicization of the remained extra finger by the concept of Buck- Gramcko.

Physical examination revealed bad flexion of the extra index and good flexion of the rest extra fingers; including the middle finger. So, the extra index was excluded from the list of choice of the new thumb. While the extra middle finger was prepared for the pollicization.


















.....

In another context, one could read:

- [*Neural Conduction, Personal View vs. International View \(Innovated\)*](#)



[*Neural Conduction, Action Pressure Waves \(Innovated\)*](#)

-  [*Neural Conduction, Action Potentials \(Innovated\)*](#)
-  [*Neural Conduction, Action Electrical Currents \(Innovated\)*](#)
-  [*The Function of Action Potentials \(Innovated\)*](#)
-  [*The Three Phases of Neural Conduction*](#)
-  [*Neural Conduction in the Synapse \(Innovated\)*](#)
-  [*Sensory Receptors*](#)
- [*Nodes of Ranvier, the Equalizers \(Innovated\)*](#)
-  [*Nodes of Ranvier, the Functions \(Innovated\)*](#)
-  [*Nodes of Ranvier, Function N1 \(Innovated\)*](#)
-  [*Nodes of Ranvier, Function N2 \(Innovated\)*](#)
-  [*Nodes of Ranvier, Function N3 \(Innovated\)*](#)
- [*The Philosophy of Pain, Pain Comes First! \(Innovated\)*](#)
- [*The Philosophy of Form \(Innovated\)*](#)
- [*Spinal Injury, pathology of Spinal Shock, Pathology of Hyperreflexia*](#)
-  [*Spinal Shock \(Innovated\)*](#)
-  [*The Clonus \(Innovated\)*](#)
-  [*Hyperactivity Hyperreflexia \(Innovated\)*](#)
-  [*Hyperreflexia, Extended Sector of Reflex*](#)
-  [*Hyperreflexia, Bilateral Responses*](#)
-  [*Hyperreflexia, Multiple Responses*](#)
- [*Nerve Conduction Study, Wrong Hypothesis is the Origin of Misinterpretation \(Innovated\)*](#)
-  [*Wallerian Degeneration \(Innovated\)*](#)



Neural Regeneration (Innovated)

-

Wallerian Degeneration Attacks Motor Axons, While Avoids Sensory Axons



Barr Body, the Whole Story (Innovated)



Boy or Girl, Mother Decides!



Adam's Rib and Adam's Apple, Two Faces of one Sin



The Black Hole is a (the) Falling Star?



Adam's Rib, could be the Original Sin?



Pronator Teres Syndrome, Struthers like Ligament (Innovated)

20/7/2015