

Mandible Reconstruction Using Free Fibula Flap

Since 1983, the free fibula flap gains the domains each after the other. The side effects of its harvest in site donor are well tolerated. Whereas the benefits of its implantation in site recipient are of great value. Previously, in three reported cases, I presented some examples of its valuable contributions in plastic surgery; the maxilla, the radius bone, and the ulna bone reconstruction. Herein, I will present another reported case concerning the mandible reconstruction using the same versatile flap. The patient is a 31-year-old female, was a victim of a gun shout. She lost the total nose, the middle portion of the maxilla, and the anterior arc of the mandible. The total left horizontal ramus, the total chin bone, and most of the right horizontal ramus of the mandible were absent; figures (1), (2), (3).

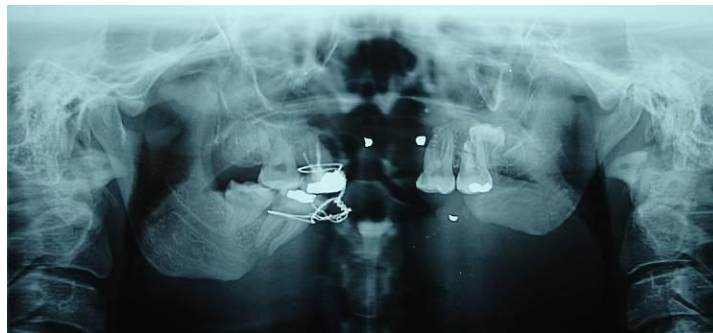

Figure (1)

Panoramic dental X-ray reveals the bone defects in the nose, the maxilla, and the mandible. In the mandible, the total left horizontal ramus, chin bone, and most of the right horizontal ramus, all are absent.

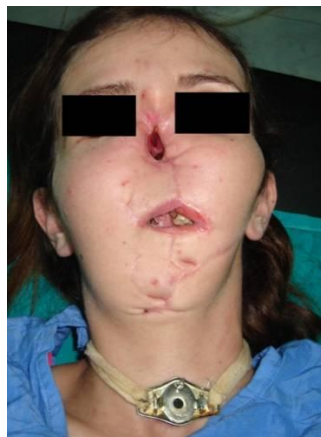

Figure (2)

Pre-operation face photo

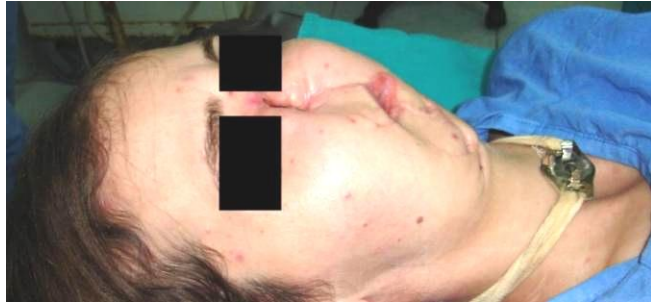

Figure (3)
Pre-operation profile

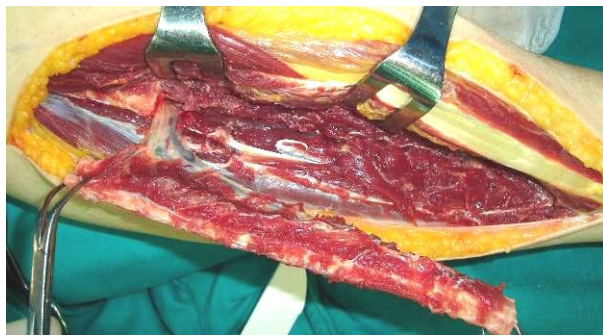

Figure (4)
Fibula flap is still in place connected to its pedicle

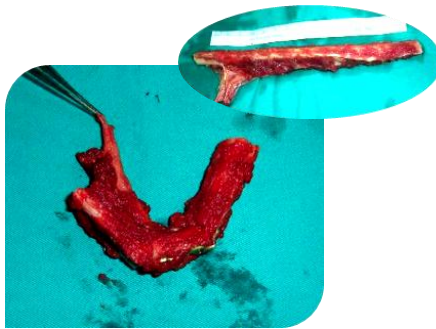


Figure (5)
The upper photo: the free fibula flap, of 16cm long, is harvested with its vascular pedicle.
The main photo: the fibula is reformed as a horse-shoe like in order to replace the mandible bone lost.
The forceps indicates to the vascular pedicle.

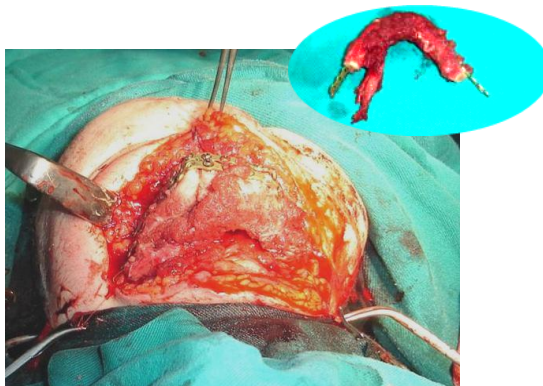


Figure (6)

The upper photo: The fibula flap is reformed as a horse-shoe like in order to replace the bone defect in mandible.

The principal photo: The reformed free fibula flap in its final place. The vascular pedicle of the flap is anastomosed to the right facial pedicle.

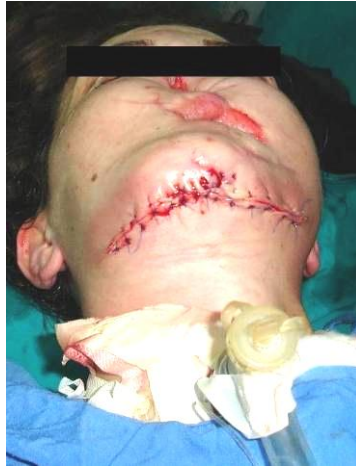

Figure (7)

Post-operative photo from below

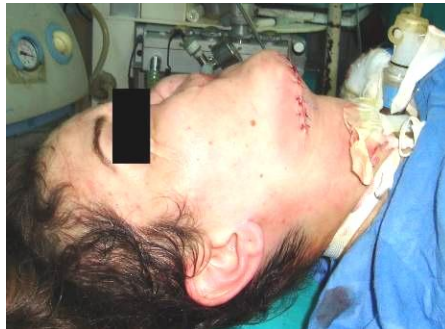

Figure (8)

Post-operation profile photo

(*) More reported cases of using the Free Fibula Flap in bone reconstruction on these links (Personal Archives):

- 1- [Maxilla Reconstruction.](#)
- 2- [Mandible Reconstruction.](#)
- 3- [Ulna Reconstruction.](#)
- 4- [Tibia reconstruction in case of recalcitrant osteitis \(1\).](#)
- 5- [Tibia Reconstruction \(2\).](#)
- 6- [Radius Reconstruction \(1\).](#)
- 7- [Radius Reconstruction \(2\).](#)

In another context, one could read:

- [Neural Conduction, Personal View vs. International View \(Innovated\)](#)

 [Neural Conduction, Action Pressure Waves \(Innovated\)](#)

 [Neural Conduction, Action Potentials \(Innovated\)](#)

 [Neural Conduction, Action Electrical Currents \(Innovated\)](#)

 [The Function of Action Potentials \(Innovated\)](#)

 [The Three Phases of Neural Conduction](#)

 [Neural Conduction in the Synapse \(Innovated\)](#)

 [Sensory Receptors](#)

- [Nodes of Ranvier, the Equalizers \(Innovated\)](#)

 [Nodes of Ranvier, the Functions \(Innovated\)](#)

 [Nodes of Ranvier, Function N1 \(Innovated\)](#)

 [Nodes of Ranvier, Function N2 \(Innovated\)](#)

 [Nodes of Ranvier, Function N3 \(Innovated\)](#)

- [The Philosophy of Pain, Pain Comes First! \(Innovated\)](#)

- [The Philosophy of Form \(Innovated\)](#)

- [Spinal Injury, pathology of Spinal Shock, Pathology of Hyperreflexia](#)

 [Spinal Shock \(Innovated\)](#)

 [The Clonus \(Innovated\)](#)

 [Hyperactivity Hyperreflexia \(Innovated\)](#)

 [Hyperreflexia, Extended Sector of Reflex](#)

 [Hyperreflexia, Bilateral Responses](#)

 [Hyperreflexia, Multiple Responses](#)

- [Nerve Conduction Study, Wrong Hypothesis is the Origin of](#)

Misinterpretation (Innovated)



[Wallerian Degeneration \(Innovated\)](#)



[Neural Regeneration \(Innovated\)](#)

- [Wallerian Degeneration Attacks Motor Axons, While Avoids Sensory Axons](#)



[Barr Body, the Whole Story \(Innovated\)](#)



[Boy or Girl, Mother Decides!](#)



[Adam's Rib and Adam's Apple, Two Faces of one Sin](#)



[The Black Hole is a \(the\) Falling Star?](#)

31/10/2014