

Biceps Femoris' Long Head Syndrome (BFLHS)

Biceps Femoris' long head syndrome is a nerve compression syndrome (NCS) concerning the sciatic nerve (SN). In its passage around the long head of the biceps femoris muscle (LHBFM), in the inferior gluteal and the posterior femoral regions, the proximal fibrous segment of the tendon may irritate the SN. Its incidence is rare and may come at the tail of the causative list of Sciatica; i.e. far after the disc herniation and the Piriformis syndrome. It affects most often the young athletic males.

The major relevant complain is the pain of the posterior femoral region. The patient describes his pain as that of the muscle crumb. At the beginning, the pain is mild and related to stressing the muscles of the lower extremities. Some activities such as stairs climbing and alternation of squatting and standing up, frequently seen in some sports and some manual professions, often solicit the pain. At the end, the pain becomes hard and persistent even in the rest. At its apogee, the pain precludes walking and standing up on the affected lower extremity. Most often, one could distinguish a story of trauma to the posterior femoral region.

In fact, the traumas to the posterior femoral region are frequent and sometimes are of high energy. In contrast, the incidence of BFLHS itself is too little. Thus, there should be some reasons other than the only trauma for the syndrome to take place in a specific individual.

I recognized two pathologies of the BFLHS. The first is well known to the medical world. It concerns a medial deviation of the SN course. The SN exaggerates in approaching the ischial tubercle. In such situation, the nerve is permanently exposed to the irritative impact of the proximal insertion of the LHBFM; **Figure (1)**.

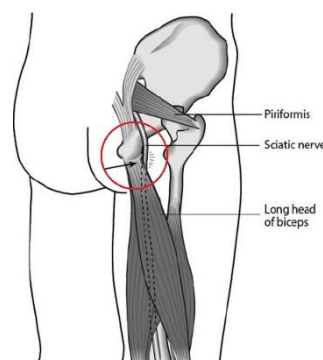


Figure (1) the theatre of action of the first etiology of the BFLHS (black arrow in the red circle).

Nearby the ischial tubercle, the SN exaggerates in approaching the proximal insertion of the LHBFM. This neighborhood is functionally condemned. The tendon does not cease to irritate the nerve. Each flexion and extension of the ilio-femoral and knee joints respectively set up the basis of the BFLHS.

The second pathology of the BFLHS is quite recent and obtained from my personal expertise. It concerns an anatomical variation of the LHBFM and its impact on the SN. The proximal fibrous tendon of LHBFM extends far in distal and reaches the midpoint of the femoral region; **figure (2)**. It sends its fibrous wide tongues everywhere in the depth of the muscle. Some of these fibrous tongues come into direct contact with the SN lying just in front of the muscle.

They scratch the SN in every motion of the neighboring joints. By time, as the silky bow might cut the strings of a violin, the repeated motions of these bands over the SN may hurt the nerve.

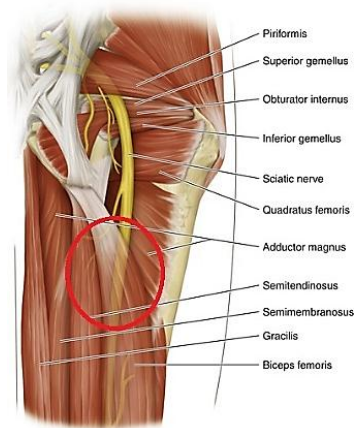


Figure (2) the theatre of action of the second etiology of the BFLHS (red circle).

The SN passes around the LHBFM for a long distance. Normally, the muscle tenderly embraces the nerve from behind. However, in certain cases, the LHBFM becomes rigid and almost fibrous compressing the SN. The femur bone anteriorly and the rigid muscle posteriorly in somehow form the famous couple anvil- hammer of the in-between SN.

Nevertheless, in such structure, the LHBFM loses some of its elasticity, and shows some aggressivity towards the SN. In somehow, the LHBFM forms the posterior blade of scissors, whose anterior one is the femur bone itself. The contraction of the LHBFM forces the two blades of scissors to meet each other squeezing the in-between SN.

CSAE REPORT

I used to refer the pain of the posterior femoral region (PFR) to the biceps femoris strain. However, the repeated failure of treatment pushed me to explore one of these clinical cases. It concerned an athletic male of 18 years. He works in a garage. He had a mild blow to his right PFR. Since, a cascade of pain and muscle crumb rolled on. He could not stand up on his right lower extremity nor walk normally. The sensation of the limb was normal. Tinel's sign was positive in the middle of the PFR. The straight leg raise test (Laseque' test) was extremely positive. In such way, any attempt to raise the straight leg was early condemned, i.e. at 0 degree approximately. All the relevant investigations failed to find out the secret of the case. However, the surgery successfully turned out the mysterious pathology. The fibrous component of the proximal tendon of the LHBFM was too long. It was descending to the midpoint of the muscle, and sending many fibrous bands everywhere in the depth of the muscle; Figure 3. The LHBFM itself was rigid compressing the SN. Two releasing cut at different levels of the LHBFM were done. The SN has been released for a large distance about the LHBFM; **figure (4)**. The outcome of the procedure was good. The patient got rid of his pain. Nowadays, he can stand up and walk normally.



Figure (3) per-operative view of the middle third of the right posterior femoral region. The fibrous segment of the proximal tendon of the LHBFM unexpectedly descends to the midpoint of the PFR (on the left). It sends many fibrous tongues in the depth of the muscle. Some of which were in contact with the SN. The semitendinosus muscle is on the right of the picture.

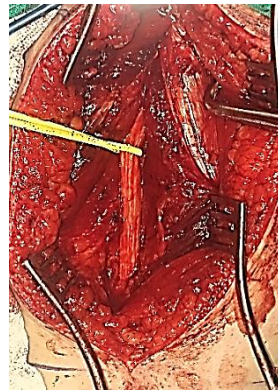


Figure (4) Per-operative view of the middle third of the right posterior femoral region. The right sciatic nerve (encircled by the yellow loop) has been liberated for a long distance about the LHBFM (on the left of the photo). The abnormally extending white matter of the proximal tendon of the LHBFM has been incised at two levels in order to weaken the hypertonic muscle. Moreover, all its fibrous tongues, dispersing in the depth of the muscle, have also been incised for more comfort to the SN.

DISCUSSION

The Biceps Femoris' Long Head Syndrome (BFLHS), should it be placed in competition with the biceps femoris strain in the list of differential diagnosis?

Answering this question might need more time for two reasons. First, the term itself is quite innovated. Personally, I did not previously read about it nor did find similar syndrome in the medical literature. Second, one reported case in the archive of an individual could not per se give an idea the force that renders it an irrefutable concept.















Actually, I created this term in order to group two etiologies of the same clinical sequences. While the first etiology is already known to the medical word; i.e. an alteration of SN pathway. In such way, the nerve abuts the proximal insertion of the LHBFM. By time, the repeated contraction of the muscle may hurt the nerve.

In contrast, the second etiology is inedited; i.e. an alteration in the structure of the proximal tendon of the LHBFM. With its overwhelming fibrous component, extending to the midpoint

of the PFR, and sending its white tongues everywhere in the depth of the muscle, the LHBFM might compress the SN over the solid femur bone.

Finally, the trauma to the PFR might have an auxiliary role in the process of the BFLHS. The trauma-induced contraction of a specific LHBFM, due to its specific structure, augments its pressure on the SN, on one hand. Putting the underlying nerve in direct contact with the rigid fibrous bands of the muscle, on the other hand. Moreover, the retained tonicity of the muscle has the potentiality to startup and/or exacerbate the process of the syndrome.

In another context, one could read:

- [Neural Conduction, Personal View vs. International View \(Innovated\)](#)
-  [Neural Conduction, Action Pressure Waves \(Innovated\)](#)
-  [Neural Conduction, Action Potentials \(Innovated\)](#)
-  [Neural Conduction, Action Electrical Currents \(Innovated\)](#)
-  [The Function of Action Potentials \(Innovated\)](#)
-  [The Three Phases of Neural Conduction](#)
-  [Neural Conduction in the Synapse \(Innovated\)](#)
-  [Sensory Receptors](#)
- [Nodes of Ranvier, the Equalizers \(Innovated\)](#)
-  [Nodes of Ranvier, the Functions \(Innovated\)](#)
-  [Nodes of Ranvier, Function N1 \(Innovated\)](#)
-  [Nodes of Ranvier, Function N2 \(Innovated\)](#)
-  [Nodes of Ranvier, Function N3 \(Innovated\)](#)
- [The Philosophy of Pain, Pain Comes First! \(Innovated\)](#)
- [The Philosophy of Form \(Innovated\)](#)
- [Spinal Injury, pathology of Spinal Shock, Pathology of Hyperreflexia](#)
-  [Spinal Shock \(Innovated\)](#)
-  [The Clonus \(Innovated\)](#)
-  [Hyperactivity Hyperreflexia \(Innovated\)](#)



[Hyperreflexia, Extended Sector of Reflex](#)



[Hyperreflexia, Bilateral Responses](#)



[Hyperreflexia, Multiple Responses](#)

-

[Nerve Conduction Study, Wrong Hypothesis is the Origin of Misinterpretation \(Innovated\)](#)



[Wallerian Degeneration \(Innovated\)](#)



[Neural Regeneration \(Innovated\)](#)

-

[Wallerian Degeneration Attacks Motor Axons, While Avoids Sensory Axons](#)



[Barr Body, the Whole Story \(Innovated\)](#)



[Boy or Girl, Mother Decides!](#)



[Adam's Rib and Adam's Apple, Two Faces of one Sin](#)



[The Black Hole is a \(the\) Falling Star?](#)

26/05/2017